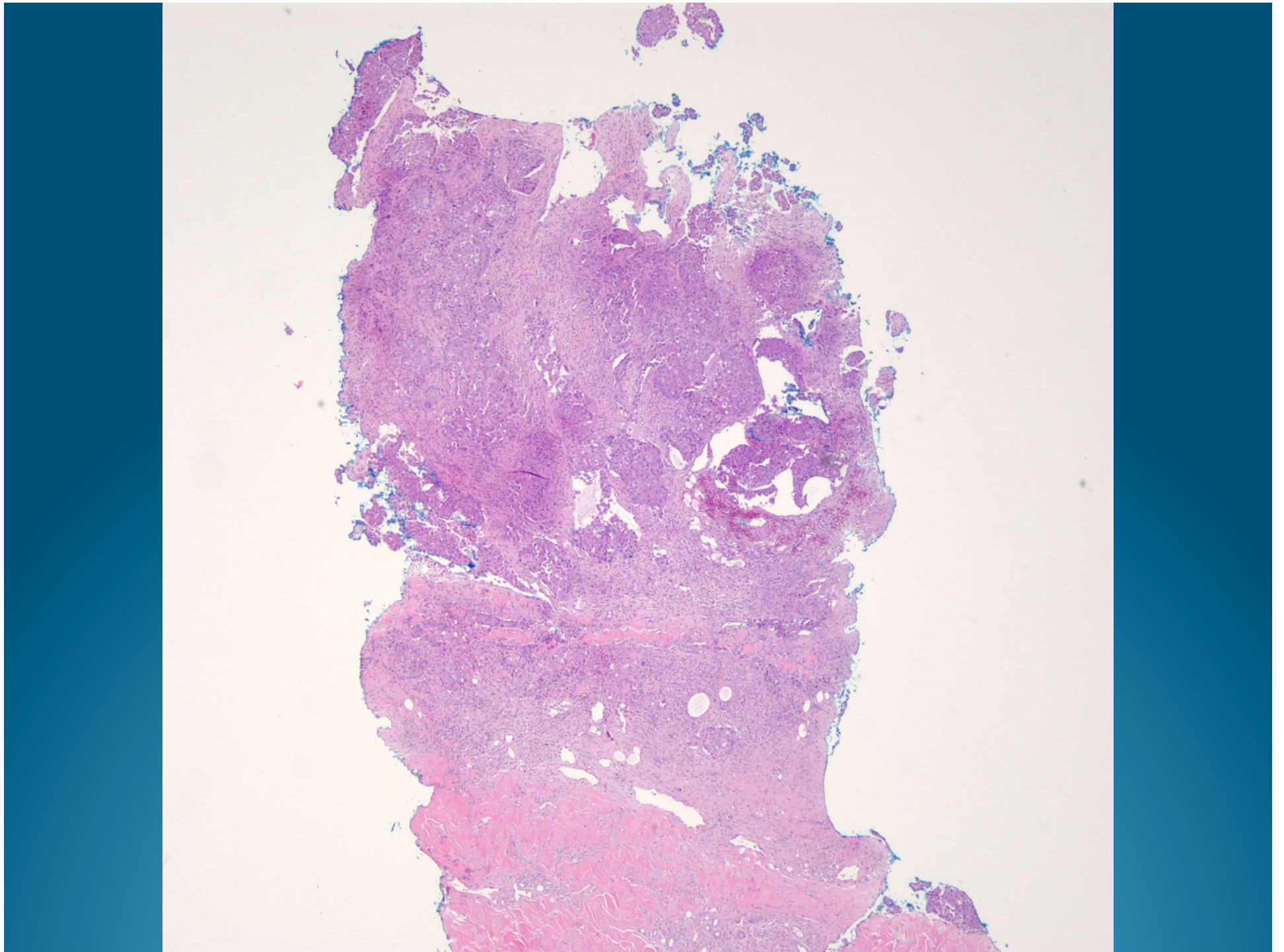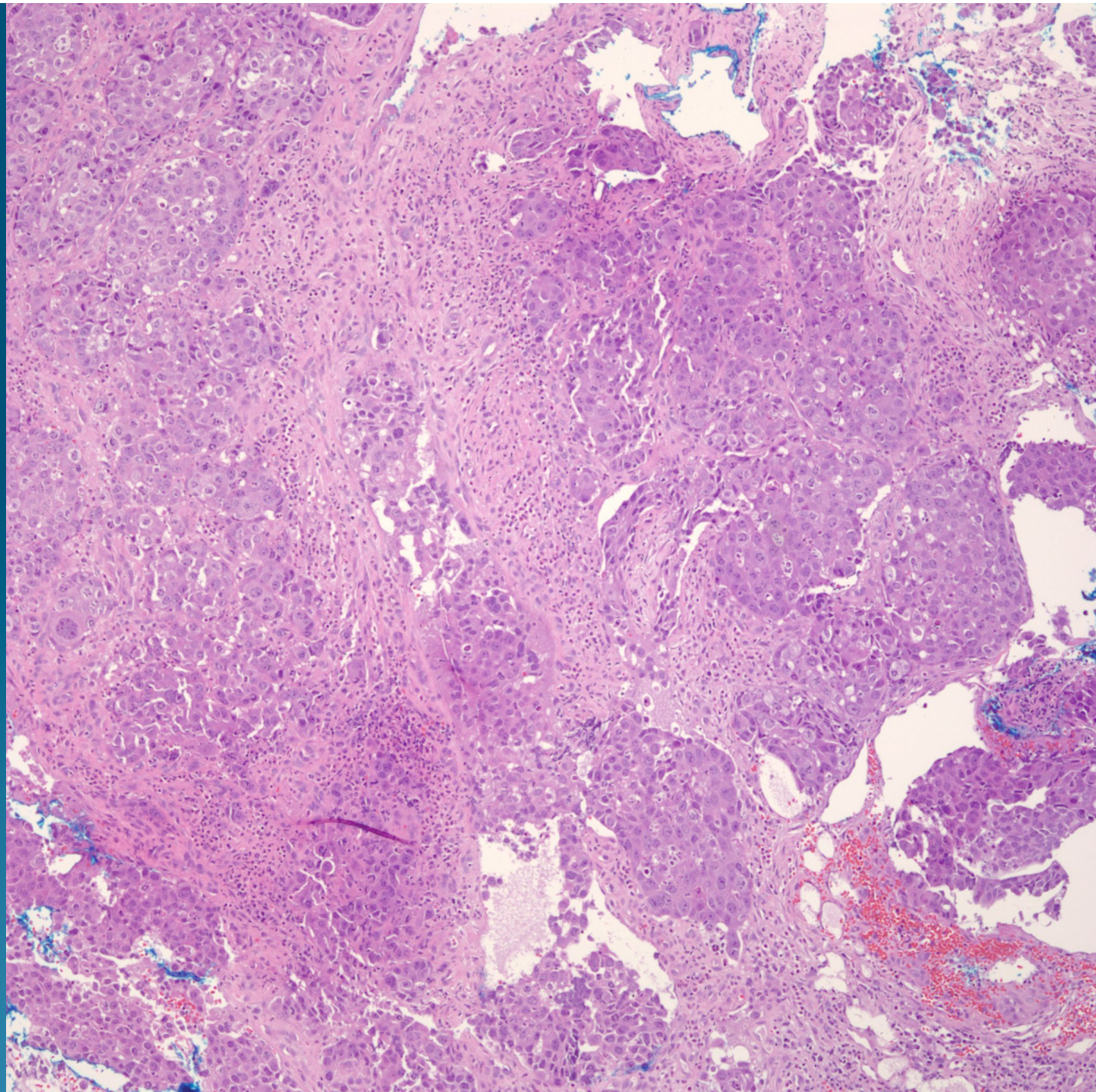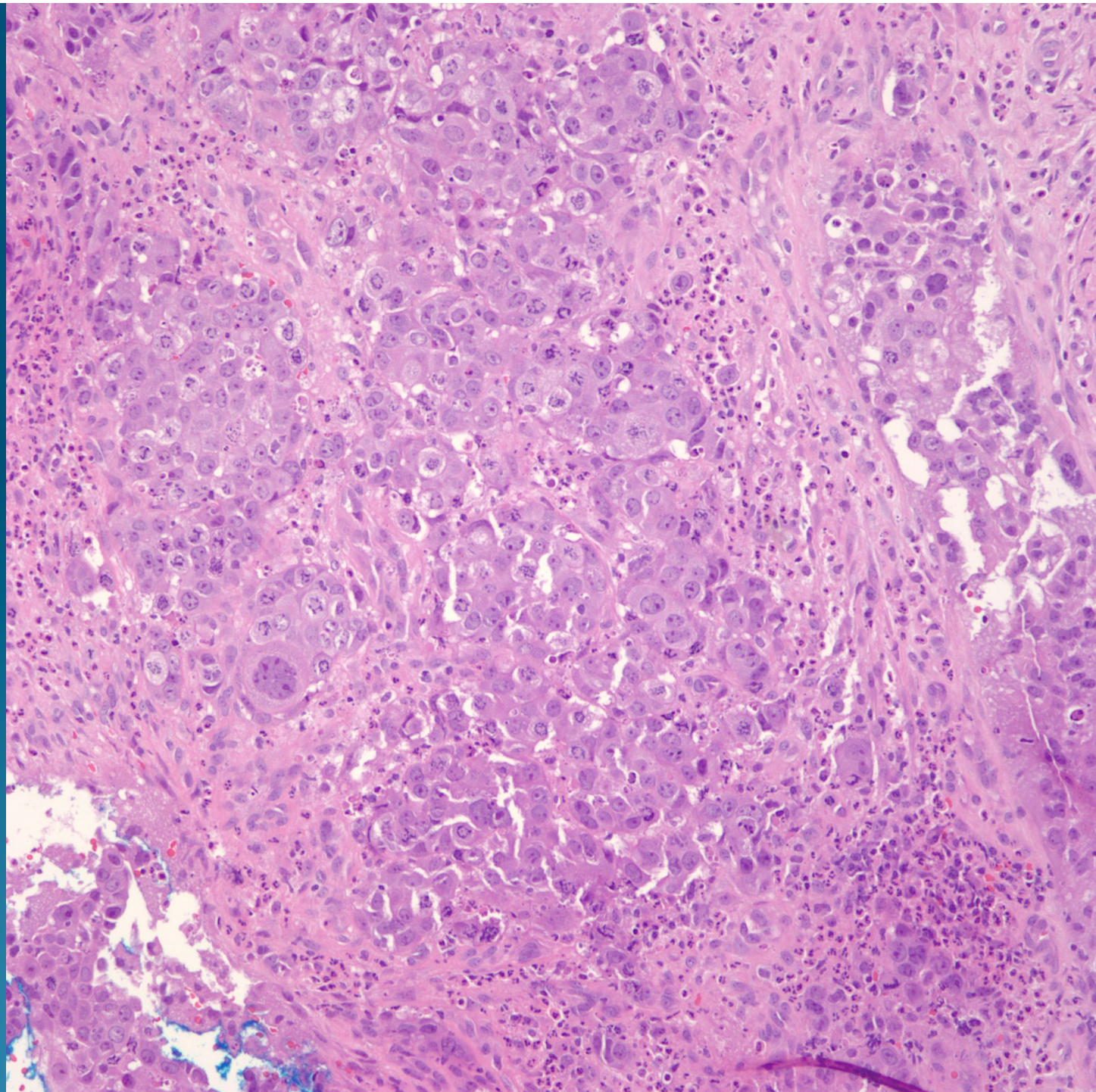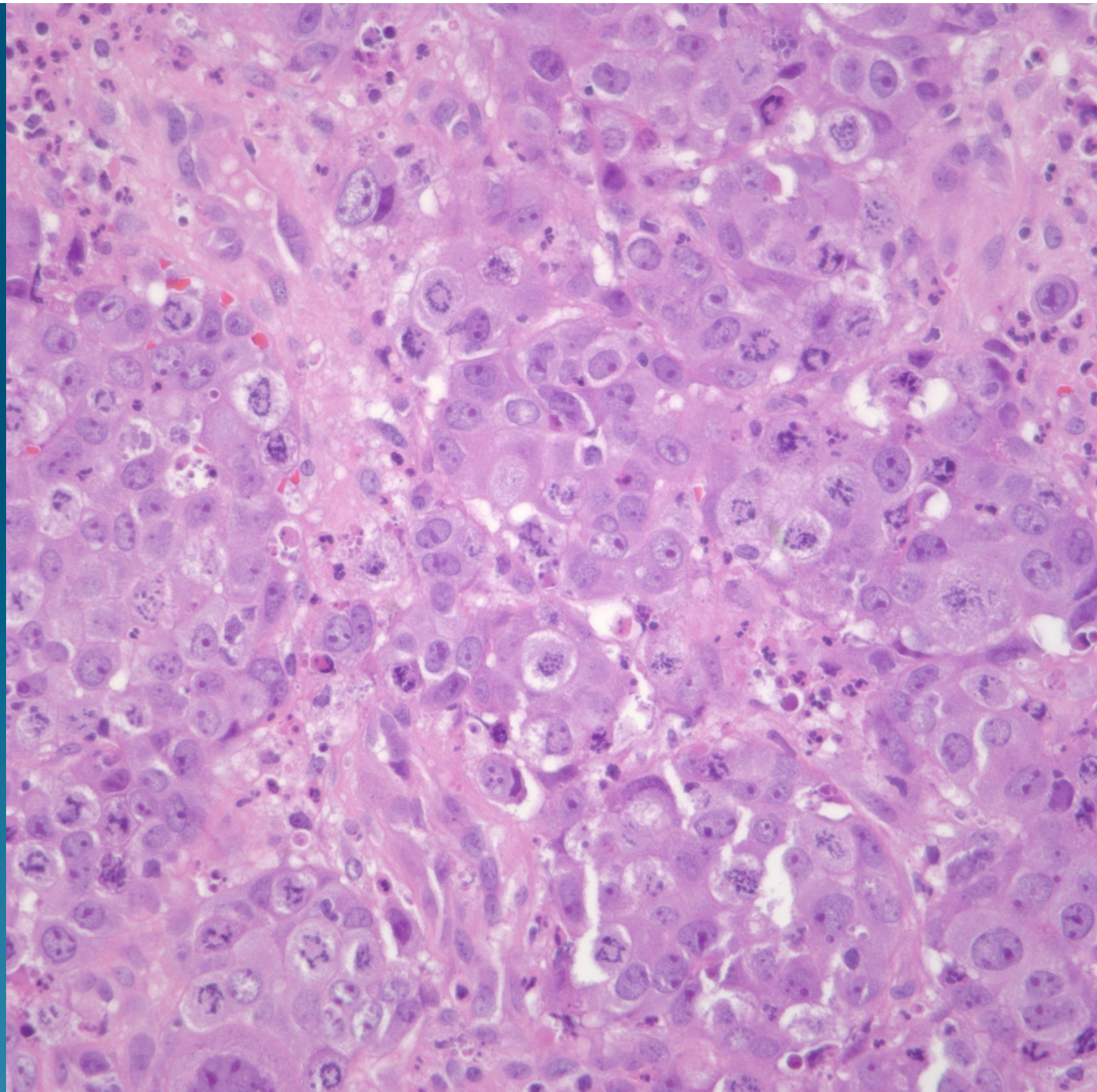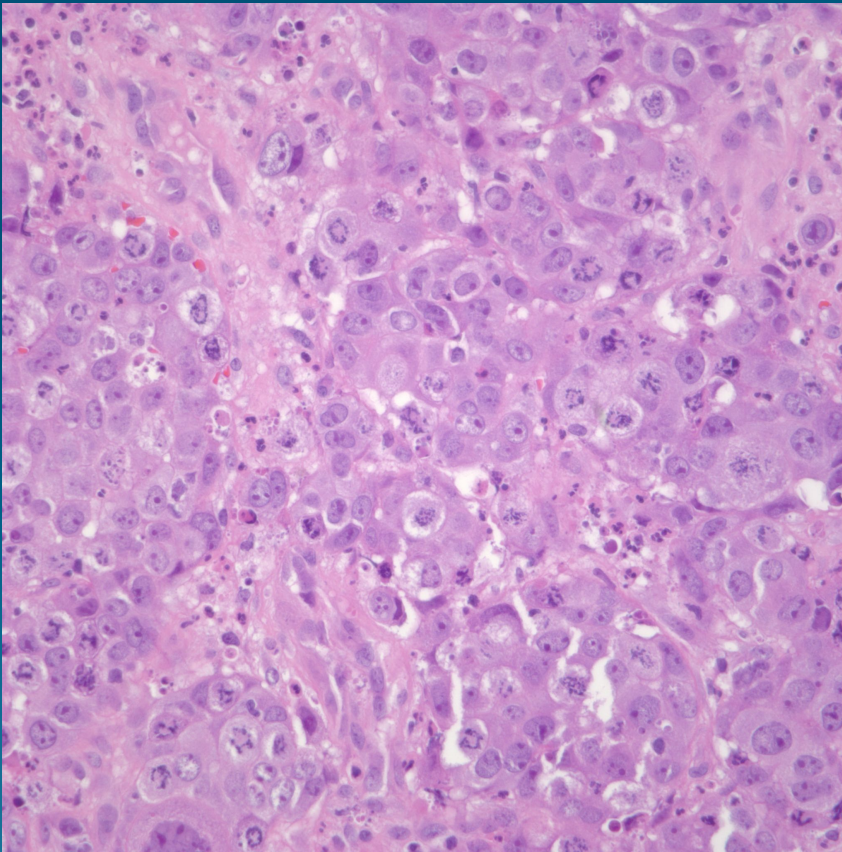


Poorly Differentiated
Adenocarcinoma of the Lung,
Metastatic to the Skin

Pearls



- Malignant cells in clusters and sheets
- May see focal glandular differentiation or cytoplasmic vacuoles-may confirm with mucin stains
- Consider multiple sources with most common primaries in a woman including breast, GI, and lung
- May need additional IHC if unknown primary